Original Investigation

Machine Learning Algorithms Utilizing Quantitative CT Features May Predict Eventual Onset of Bronchiolitis Obliterans Syndrome After Lung Transplantation

Eduardo J. Mortani Barbosa Jr, MD*, Maarten Lanclus, MSc*, Wim Vos, PhD, Cedric Van Holsbeke, PhD, William De Backer, MD, PhD, Jan De Backer, PhD, James Lee, MD

Abbreviations and Acronyms

LTx lung transplantation
FRI functional respiratory imaging
qCT quantitative CT
BOS bronchiolitis obliterans syndrome
CLAD chronic lung allograft dysfunction
FEV_1 forced expiratory volume in the first second
TLC total lung capacity
FRC functional residual capacity
iVlobe imaging lobar volume
iVaw imaging airway volume
iRaw imaging airway resistance
iSaw imaging airway surface

Rationale and Objectives: Long-term survival after lung transplantation (LTx) is limited by bronchiolitis obliterans syndrome (BOS), defined as a sustained decline in forced expiratory volume in the first second (FEV_1) not explained by other causes. We assessed whether machine learning (ML) utilizing quantitative computed tomography (qCT) metrics can predict eventual development of BOS.

Materials and Methods: Paired inspiratory-expiratory CT scans of 71 patients who underwent LTx were analyzed retrospectively (BOS [$n = 41$] versus non-BOS [$n = 30$]), using at least two different time points. The BOS cohort experienced a reduction in FEV_1 of >10% compared to baseline FEV_1 post LTx. Multifactor analysis correlated declining FEV_1 with qCT features linked to acute inflammation or BOS onset. Student *t* test and ML were applied on baseline qCT features to identify lung transplant patients at baseline that eventually developed BOS.

Results: The FEV_1 decline in the BOS cohort correlated with an increase in the lung volume ($P = .027$) and in the central airway volume at functional residual capacity ($P = .018$), not observed in non-BOS patients, whereas the non-BOS cohort experienced a decrease in the central airway volume at total lung capacity with declining FEV_1 ($P = .039$). Twenty-three baseline qCT parameters could significantly distinguish between non-BOS patients and eventual BOS developers ($P < .05$), whereas no pulmonary function testing parameters could. Using ML methods (support vector machine), we could identify BOS developers at baseline with an accuracy of 85%, using only three qCT parameters.

Conclusions: ML utilizing qCT could discern distinct mechanisms driving FEV_1 decline in BOS and non-BOS LTx patients and predict eventual onset of BOS. This approach may become useful to optimize management of LTx patients.

Key Words: Lung transplantation; quantitative CT metrics; computer-assisted image processing; lung transplant rejection; bronchiolitis obliterans syndrome.

© 2018 The Association of University Radiologists. Published by Elsevier Inc. All rights reserved.

Acad Radiol 2018; 25:1201–1212

From the Perelman School of Medicine, University of Pennsylvania, Departments of Radiology and Medicine, 3400 Spruce Street, Philadelphia, PA 19104 (E.J.M.B., J.L.); FLUIDDA nv, Kontich, Belgium (M.L., W.V., C.V.H., J.D.B.); University Hospital Antwerp, Department of Respiratory Medicine, Edegem, Belgium (W.D.B.).
Received October 11, 2017; revised January 9, 2018; accepted January 10, 2018. *EB and ML contributed equally to this article. **Address correspondence to:** E.J.M.B. e-mail: Eduardo.Barbosa@uphs.upenn.edu

© 2018 The Association of University Radiologists. Published by Elsevier Inc. All rights reserved.
https://doi.org/10.1016/j.acra.2018.01.013

INTRODUCTION

Lung transplantation (LTx) is an important treatment option for patients with advanced, irreversible lung disease (1). However, despite continued advancements in LTx techniques, long-term survival is limited by chronic lung allograft dysfunction (CLAD). The obstructive phenotype of CLAD is a form of chronic immune-mediated rejection that causes an obliterative bronchiolitis resulting in progressive airflow obstruction over time and eventual allograft failure and death (2,3). Because histopathologic confirmation of obliterative bronchiolitis is impractically obtained with surgical lung biopsy, given risks and cost, the clinically defined term bronchiolitis obliterans syndrome (BOS) was introduced (2). BOS is defined as a sustained decline in the forced expiratory volume in the first second (FEV_1) of the transplanted patient from the peak baseline post-transplant value not associated with other potential reversible causes such as pulmonary infections or pulmonary edema (2,3). Stage BOS 0-p is defined as a decline in FEV_1 of >10% from peak post-LTx FEV_1 (2,4).

The onset of BOS is associated with poor survival, with a median survival of 2.5 years after its onset (3,5). Its incidence is highest during the first 2 years after transplantation, but patients remain at risk indefinitely, and the cumulative incidence reaches more than 50% after 5 years (6). Although advances in LTx technique and postoperative care have resulted in improved short-term outcomes, there has been no substantial decrease in the incidence of BOS (5). Additionally, no effective treatments have been established yet, although there is evidence suggesting augmented immunosuppression may stabilize or cause regression of the disease if diagnosed in the early stages (7). Also, as BOS affects the small airways of the allograft, it may be that, by the time it is clinically diagnosed, a large proportion of the allograft airways have already been irreversibly affected. Therefore, earlier detection of BOS is of great interest because it might increase the probability of successful treatment with novel therapeutic agents in future clinical trials.

Currently, imaging is not consistently established as a diagnostic tool in lung transplant recipients to evaluate BOS (1). Nevertheless, previous studies have shown that standard high-resolution computed tomography (HRCT) scans may be useful in the management of post-transplant patients (1,3).

In the present study, quantitative computed tomography (qCT) metrics using functional respiratory imaging (FRI), a method based on HRCT quantitative computational image processing of lung parenchyma and airways, was used to assess post LTx changes in lung and airway structure and function. These changes were correlated with the onset of BOS as defined by sustained FEV_1 decline, and differentiated from other nonsustained mechanisms of FEV_1 decline in non-BOS subjects. FRI offers the possibility to extract regional lung parenchyma and airway information, allowing investigation of which regions in the transplanted lungs drive the decline in FEV_1. The second part of the present study evaluated the prospect of early-stage BOS detection by means of predictive modeling, assessing the ability of qCT FRI parameters to identify LTx patients at baseline (first visit after transplant) that will eventually develop BOS, on subsequent follow-up. Identifying key regions and changes in qCT FRI parameters in the lungs of patients affected by early, preclinical bronchiolitis obliterans and characterizing disease progression regionally can lead to an earlier diagnosis of BOS and potentially improved outcomes.

MATERIALS AND METHODS

Study Population

The present study was approved by the local institutional review board and was Health Insurance Portability and Accountability Act compliant. Patients were selected retrospectively by a board-certified cardiothoracic radiologist using the following inclusion criteria: status post unilateral or bilateral LTx, availability of at least two chest CTs performed at least 3 months apart, availability of pulmonary function testing (PFT) performed within 2 weeks of the date of each chest CT, and availability of volumetric paired inspiratory and expiratory CTs with thin-section (1 mm or less) contiguous reconstruction. Image quality was reviewed and poor quality CT scans were excluded. PFT data were collected and reviewed by a board-certified pulmonologist. All patient identifiers were removed, and the anonymized CT and clinical and PFT data were transferred to an outside facility for computational imaging analysis of the CT data. A total of 71 LTx patients with paired inspiratory and expiratory CTs were analyzed (Table 1).

Patients were divided into two groups: LTx with BOS (41 patients) and LTx without BOS (30 patients), based on clinical information in the electronic medical record, reviewed by a board-certified pulmonologist. BOS was defined using standard diagnostic criteria requiring a sustained decline of at least 10% of FEV_1 from the best baseline postoperative measure

TABLE 1. Patient Characteristics

Study Population	
Total subjects	71 (41 BOS and 30 non-BOS)
Gender	Male: 53, female: 18
Transplant type	14 right, 17 left, 40 bilateral
BOS onset	19 early onset (15 ± 9 mo after LTx), 13 late onset (56 ± 26 mo after LTx), 9 unknown
Pretransplant diagnosis	26 IPF, 23 COPD, 7 CF, 5 A1AD, 10 other
Number of scans per patient	3 ± 1 scans (mean ± SD), ranging from 2 to 8
Follow-up HRCT scans	4.1 ± 3.3 y (mean ± SD) after transplant, ranging from 15 d to 13 y

A1AD, alpha-1-antitrypsin deficiency; BOS, bronchiolitis obliterans syndrome; CF, cystic fibrosis; COPD, chronic obstructive pulmonary disease; HRCT, high-resolution computed tomography; LTx, lung transplantation; SD, standard deviation.

TABLE 2. Time to Bronchiolitis Obliterans Syndrome Onset

Type of Onset	Number of Patients	Median Time After Transplantation	*P* Value
Early onset	19	15 ± 9 months	.1354
Late onset	13	56 ± 26months	
Unknown	9	Unknown	

of FEV_1. Baseline FEV_1 post LTx was defined as the average of the two best FEV_1 measurements at least 3 weeks apart. The PFT performed closest to each scan were examined to evaluate if the patient met the criteria for BOS 0-p (≥10% decline in FEV_1 or ≥25% decline in forced expiratory flow 25%–75%) at the time of the CT scan. BOS 0-p grade was chosen as it takes into account subtle decreases in FEV_1 (8,9) and therefore correlates with early disease.

The 71 patients (53 men and 18 women) analyzed had an age range of 25–70 years old at the time of the first scan (mean age 57 years old). Indications for LTx were idiopathic pulmonary fibrosis ($n = 26$), chronic obstructive pulmonary disease ($n = 23$), cystic fibrosis ($n = 7$), alpha 1-antitrypsin deficiency ($n = 5$), and other ($n = 10$). A total of 40 subjects underwent bilateral LTx, 14 were single right unilateral lung transplants, and 17 were single left unilateral lung transplants.

The number of follow-up paired HRCT scans ranged from 2 to 8, with the CT scans obtained between 15 days and 13 years after LTx. Of the BOS population, 19 patients had early-onset BOS (median time to onset after transplantation of 15 ± 9 months) and 13 patients had late-onset BOS (median time to onset after transplantation of 56 ± 26 months). Distinction between early and late onset of BOS was made on a 2-year (24 months) mark. Nine patients were missing a precise date of BOS diagnosis because of unavailable spirometric data to calculate baseline FEV_1, and for these patients, determination of BOS final status was made based on a combination of clinical and serial PFT data. The median duration of follow-up after the occurrence of BOS was not statistically different between patients with early-onset BOS and patients with late-onset BOS ($P = .13$) (Table 2).

The baseline prediction of BOS development included a total of 41 patients from the original population, based on completeness of datasets. Patients with missing values for certain regional parameters, because of patient-specific pathologies (such as lobar atelectasis), were not included for the feature selection methods of the supervised machine learning (ML) classifier. In this cohort of 41 patients, 15 patients were BOS developers (5 bilateral, 5 left, and 5 right transplants) and 26 patients were non-BOS developers (20 bilateral, 4 left, and 2 right transplants). None of the patients were considered BOS positive at baseline (first visit after transplant).

qCT Imaging Processing (with FRI)

CT scan data was converted into three-dimensional (3D) models of airways and lung lobes using Mimics (Materialise, Leuven, Belgium), a commercially available validated software package (Food and Drug Administration, K073468; Conformité Européenne certificate, BE 05/1191.CE.01). Other software packages used included TGrid 14.0 (Ansys Inc, Canonsburg, PA) for 3D meshing and Fluent 14.0 (Ansys Inc) for computational fluid dynamics simulations.

Segmentation of the tracheobronchial tree was done, using directional thresholding with automated leakage detection. Automatic airway segmentation was performed up to the point where no distinction could be made between the intraluminal and alveolar air. After automated segmentation of the bronchial tree, the airways were manually checked. Missing branches were added to the bronchial tree and incorrect branches were deleted when necessary. The respiratory tract was reconstructed down to the level of airways with a diameter of 1–2 mm. Beyond this point, the HRCT resolution is insufficient to distinguish alveolar and intraluminal air. The segmented airway tree was converted into a 3D model that was smoothed using a volume compensation algorithm. The smoothed model was trimmed perpendicular to the airway centerline at the trachea (using the middle point of the superior side of the sternum as a landmark) and at each terminal bronchus. Remaining artifacts due to noise in the CTs were then manually removed from the model. Finally, a series of manual quality checks was performed by FLUIDDA's team. The total time for the automated steps and manual quality checks varied from 2 to 6 hours per scan.

FRI comprises a combination of airway segmentation, lung volume segmentation by lobe, and airway resistance calculations based on computational flow simulation, allowing calculation of lobar volumes (imaging lobar volume), airway volumes (imaging airway volume), and airway resistances (imaging airway resistance). The airways were subsequently divided in central and distal regions. The central airway volume is defined as the region from the trachea until the segmental bronchi (the combination of the trachea, left main bronchus, right main bronchus, bronchus intermedius, right upper lobe bronchus, right middle lobe bronchus, right lower lobe bronchus, left upper lobe bronchus, superior division bronchus, lingular bronchus, and left lower lobe bronchus). The distal airway volume is defined as the segmented airway volume starting from the third bifurcation (fourth generation), which include segmental bronchi (B1R, B2R, etc.) and subsegmental bronchi that are discernible on the scan (bronchi with a diameter of >1–2 mm) (Fig 1) (10). Lung and lobar volumes (imaging lobar volume) from the CT images at functional residual capacity (FRC) (eg, expiratory CT) and total lung capacity (TLC) (eg, inspiratory CT) were also extracted (Fig 1). By means of application of computational fluid dynamics on the segmented airway model, airway resistance (imaging airway resistance) was calculated (11). Lungs were split into lobes by identification of the fissure lines from the CT scan. This method allows determination of the total lung volume and of the volume of each lobe individually.

FRI has been validated by comparison with gamma scintigraphy and single-photon emission computerized tomography

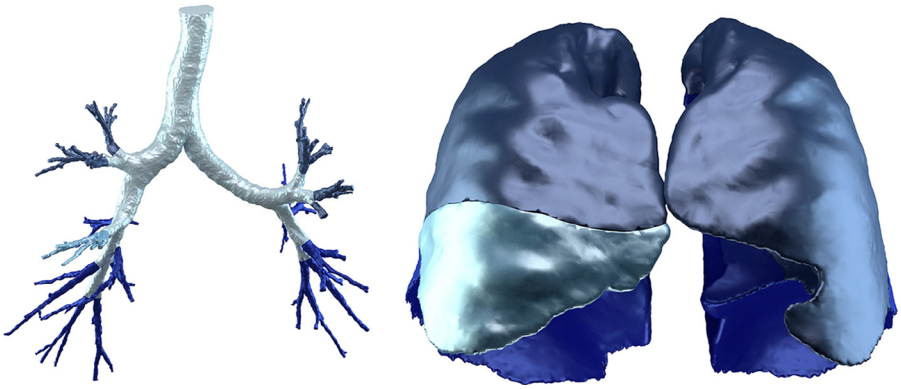

Figure 1. Central and distal airways (*left*) and lobe volumes (*right*) as defined by FLUIDDA's segmentation process. The central airway volume is defined as the region from the trachea until the segmental bronchi (the combination of the trachea, left main bronchus, right main bronchus, truncus intermedius, right upper lobe bronchus, right middle lobe bronchus, right lower lobe bronchus, left upper lobe bronchus, superior division bronchus, lingular bronchus, and left lower lobe bronchus). The distal airway volume is defined as the segmented airway volume starting from the third bifurcation (fourth generation), which includes segmental bronchi (B1R, B2R, etc.) and subsegmental bronchi that are discernible on the scan (bronchi with a diameter of >1–2 mm).

TABLE 3. Changes in FRI Parameters Related to Declines in FEV_1

FRI Parameter	BOS	Non-BOS	*P* Value	Conditional R^2
FRC lung volume	Increase	No change	.027	0.86
TLC iVaw central	No change	Decrease	.039	0.89
FRC iVaw central	Increase	No change	.018	0.70

BOS, bronchiolitis obliterans syndrome; FEV_1, forced expiratory volume in the first second; FRC, functional residual capacity; FRI, functional respiratory imaging; iVaw, imaging airway volume; TLC, total lung capacity.

(11,12). This technique has been used in prior studies to assess the effect of pharmacologic interventions in the airways of patients with asthma and patients with COPD (13–15).

Statistical Analysis

Because of the regional heterogeneous nature of the data, linear–mixed effect analyses were performed. FRI parameters were considered predictor variables, BOS status was considered as the outcome variable, and FEV_1 and their interaction terms were considered as fixed effects, whereas each subject was considered a random factor. As the dataset is longitudinal, a random slope for BOS was introduced. Based on this model, *P* values were generated based on the Satterthwaite approximation for degrees of freedom. Interaction contrasts were introduced to clarify the research question. The significance level was set at 0.05, and the level for observing a trend was set at 0.1. Gender and age were not used as controls in the mixed effects models, because they are inherently present and intrinsically considered in all FRIs and spirometric percent predicted parameters.

For the baseline prediction of BOS development, initially Student *t* test was applied to assess individual biomarkers with significant predictive power for eventual BOS development. The significance level was set at 0.05. Next, supervised ML with support vector machines (SVMs) was used to examine the predictive power of multiple feature combinations, using significant features derived from the Student *t* test. A radial basis functional kernel with default tuning parameters was used (cost: 1 and gamma: 1/data dimension) to enable nonlinear hyperplanes for classification purposes. Classification was performed in one-dimensional, two-dimensional, and 3D space. For one and two feature combinations (one-dimensional and two-dimensional spaces), a 90%–10% training set-to-test set ratio was used for 500 random combinations of training set-test set partitions with averaging of the overall results (accuracies). For three feature combinations (3D space), an 80%–20% training set-to-test set ratio was used for 100 random combinations of training sets-test sets partitions. All SVM models were optimized for accuracy.

All analyses were performed using the open-source statistical environment R version 3.2.5 or higher (The R Foundation for Statistical Computing, Vienna, Austria).

RESULTS

Linear–mixed effect analyses were performed to correlate the changes in FEV_1 in each cohort (BOS vs non-BOS developers) with quantitative imaging parameters to identify differences in lung function and structure. The results are summarized in Table 3, which lists qCT metrics that were statistically different between BOS and non-BOS patients. In the BOS cohort, a significant increase in total lung volume at FRC (in % predicted) was associated with sustained decline in FEV_1 ($P = .027$). This correlation was not observed for the

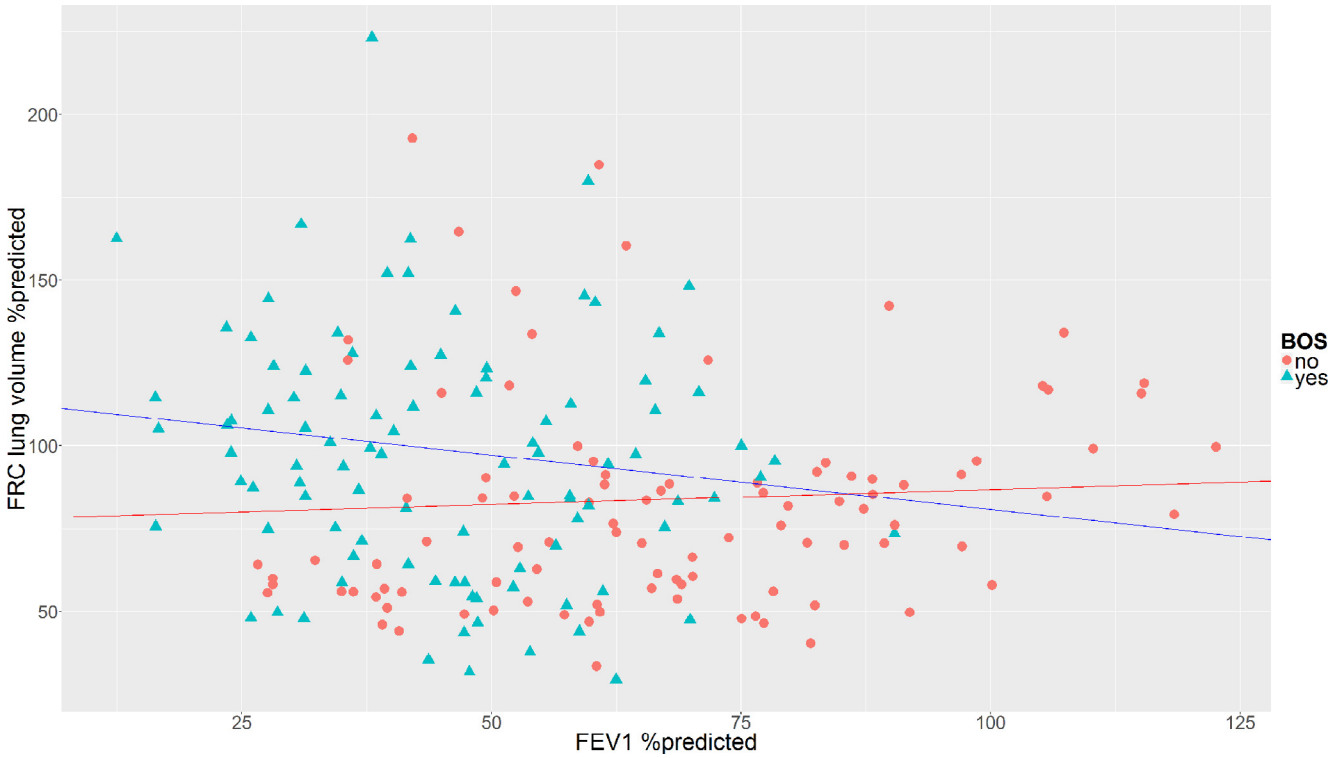

Figure 2. Correlation between FEV_1 (in % predicted) and imaging lung volume at FRC (in % predicted) for the BOS and non-BOS cohorts. The correlation for the BOS patients (in *blue*) has a negative slope, indicating that lower values of FEV_1 are associated with higher lung volumes at FRC. Non-BOS patients (in *red*) have a slope of almost zero, so the lung volume at FRC has no correlation with FEV_1. BOS, bronchiolitis obliterans syndrome; FEV_1, forced expiratory volume in the first second; FRC, functional residual capacity. (Color version of figure is available online.)

non-BOS patients, where the FRC lung volume remained constant with nonsustained or subthreshold changes in FEV_1 (Fig 2). Given that BOS is defined as a sustained decline in FEV_1, its cumulative incidence increases over time after LTx, and the increase in lung volume at FRC was also observed over time after LTx ($P < .001$), this latter result supports the validity of the previous result (Fig 3).

However, when examining the airway volume using FRI, opposite behaviors were observed in the two cohorts: whereas sustained FEV_1 decline correlates with a significant increase in the central airway volume at FRC ($P = .018$) in the BOS cohort (Fig 4), the non-BOS cohort experienced a decrease in the central airway volume at TLC ($P = .039$) (Fig 5). Changes in central airway volume at FRC were not observed for the non-BOS cohort (Fig 4), and the central airway volume at TLC for the BOS cohort also remained unchanged (Fig 5).

Figure 6 depicts the changes in imaging parameters of illustrative BOS and non-BOS patients (60 years old, male, and 59 years old, female, respectively), 4 and 2 years after the initial evaluation, respectively. Both patients underwent a bilateral lung transplant. During the follow-up period, the BOS patient had a reduction of 11.85% in predicted FEV_1 and the non-BOS patient had a reduction of 7.36% in predicted FEV_1. FRI parameters show that for these patients, the decrease in FEV_1 is associated with a completely different response in qCT biomarkers denoting different lung structural and functional changes between the BOS and the non-BOS patients, and henceforth presumably different pathophysiological mechanisms, as described in Table 3, which represents the entire study population results.

Table 4 and Figure 7 (also see Supplementary Fig S1) show the significant baseline predictors of BOS development based on the Student *t* test with a significance level of 0.05. A total of 23 baseline FRI parameters could significantly distinguish between BOS developers and non-BOS developers. Nonetheless and noteworthy, no baseline clinical or PFT parameters could distinguish between BOS and non-BOS patients. Figure 8 demonstrates that the default clinical parameters FEV_1 and FEV_1 percent predicted (FEV_1pp) are nonsignificant ($P = .3866352$ and $P = .8746998$, respectively) in terms of prediction of eventual BOS development. BOS developers show at baseline significantly smaller lobe volumes, airway volumes, and airway surfaces, and subsequently, significantly higher airway resistances.

Table 5 summarizes the results (accuracies) of the one-, two-, and 3D ML-based classification for all (significant) feature combinations. Accuracies in classification based on one feature (one-dimensional classification) range from 55% to 76%. Central and total airway volumes at FRC are the best baseline predictors for eventual BOS development with a maximal accuracy of 76%. Accuracies in classification based on two features (two-dimensional classification) range from 52% to 83%. The maximal accuracy of 83% is obtained by combining baseline

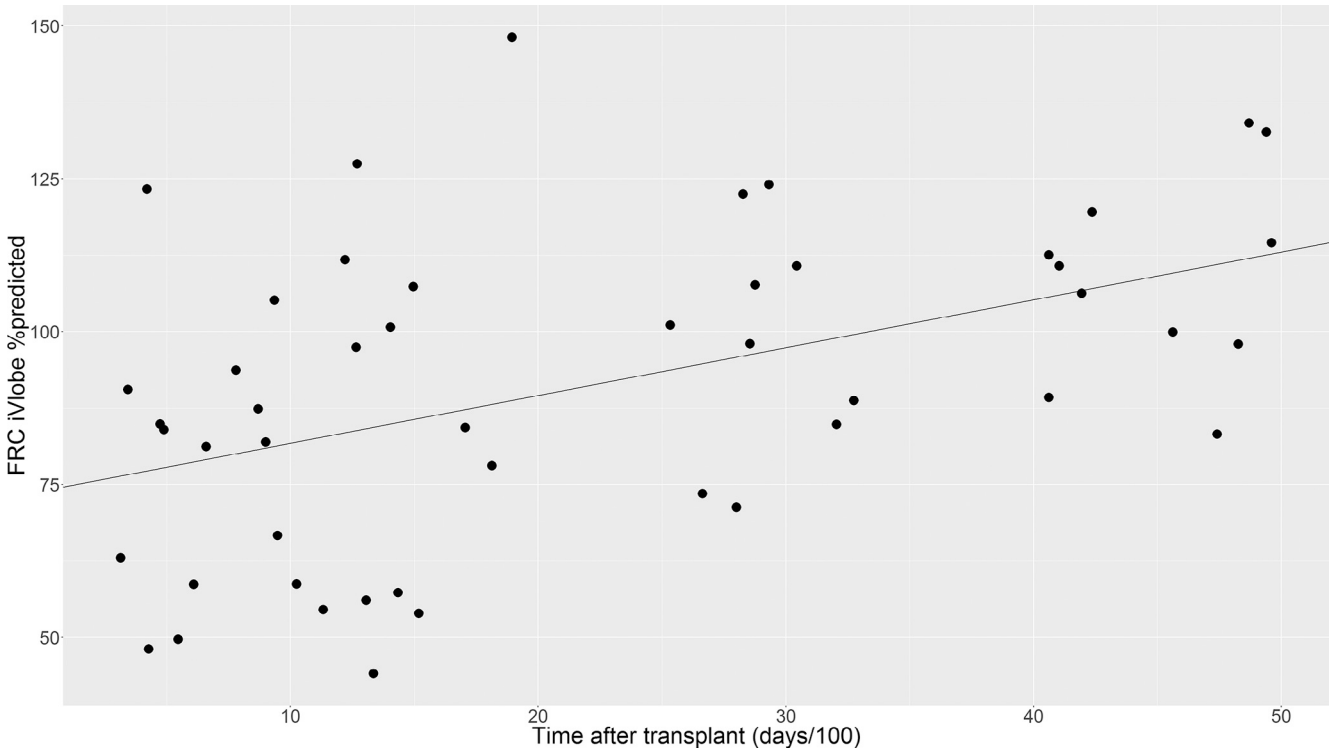

Figure 3. Change in imaging lung volume at FRC (in % predicted) over time after lung transplant (in days/100) for the bronchiolitis obliterans syndrome cohort. FRC, functional residual capacity; iVlobe, imaging lobar volume.

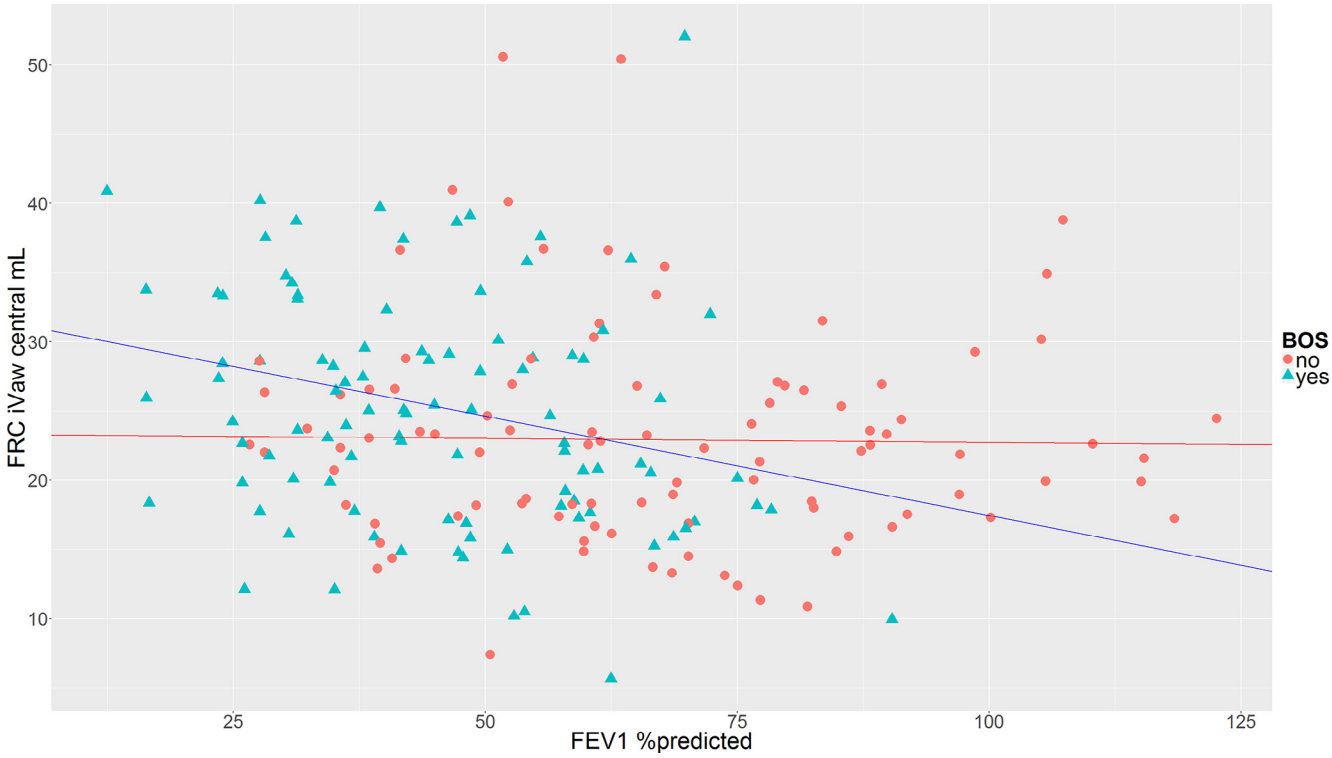

Figure 4. Correlation between FEV_1 (in % predicted) and imaging central airway volume (iVaw central) at FRC (in mL) for the BOS and the non-BOS cohorts. The correlation for the BOS patients (in *blue*) has a negative slope, indicating that lower values of FEV_1 are associated with higher central airway volumes at FRC. Non-BOS patients (in *red*) have a slope of almost zero, so the central airway volume at FRC has no correlation with FEV_1. BOS, bronchiolitis obliterans syndrome; FEV_1, forced expiratory volume in the first second; FRC, functional residual capacity; iVaw, imaging airway volume. (Color version of figure is available online.)

Figure 5. Correlation between FEV_1 (in % predicted) and imaging central airway volume (iVaw central) at TLC (in mL) for the BOS and the non-BOS cohorts. The correlation for the BOS patients (in *blue*) has a slope of almost zero, so the central airway volume at TLC has no correlation with FEV_1. Non-BOS patients (in *red*) have a positive slope, indicating that lower values of FEV_1 are associated with lower central airway volumes at FRC. BOS, bronchiolitis obliterans syndrome; FEV_1, forced expiratory volume in the first second; iVaw, imaging airway volume; TLC, total lung capacity. (Color version of figure is available online.)

TABLE 4. Significant Baseline Predictors for BOS Development (Student *t* Test)

Type	Level	Feature	Zone	*P* Value
FRI	FRC	Lobe volume (iVlobe)	RML	<.0001
FRI	FRC	Lobe volume (iVlobe predicted)	RML	<.0001
FRI	FRC	Lobe (lung) volume (iVlobe)	Right lung	.001
FRI	FRC	Lobe volume (iVlobe)	RUL	.001
FRI	FRC	Lobe volume (iVlobe predicted)	RUL	.002
FRI	TLC	Lobe volume (iVlobe predicted)	RML	.009
FRI	TLC	Lobe volume (iVlobe)	RML	.009
FRI	FRC	Lobe volume (iVlobe)	RLL	.013
FRI	FRC	Airway volume (iVaw)	LL	.015
FRI	FRC	Airway volume (iVaw)	Total	.019
FRI	FRC	Airway volume (iVaw)	LLL	.021
FRI	FRC	Airway volume (iVaw)	RLL	.025
FRI	FRC	Lobe volume (iVlobe predicted)	RLL	.027
FRI	FRC	Airway resistance (iRaw)	RUL	.031
FRI	FRC	Airway volume (iVaw)	Central	.037
FRI	FRC	Airway volume (iVaw)	Distal	.040
FRI	FRC	Airway surface (iSaw)	Total	.040
FRI	FRC	Airway volume (iVaw)	Left lung	.041
FRI	FRC	Airway surface (iSaw)	LL	.043
FRI	FRC	Airway surface (iSaw)	RLL	.045
FRI	FRC	Airway surface (iSaw)	Central	.047
FRI	FRC	Specific airway volume (siVaw)	LL	.048
FRI	FRC	Airway resistance (iRaw)	RML	.049

FRC, functional residual capacity; FRI, functional respiratory imaging; iRaw, imaging airway resistance; iSaw, imaging airway surface; iVaw, imaging airway volume; iVlobe, imaging lobar volume; LL, lower lobes (right lower lobe AND left lower lobe); LLL, left lower lobe; RLL, right lower lobe; RML, right middle lobe; RUL, right upper lobe.

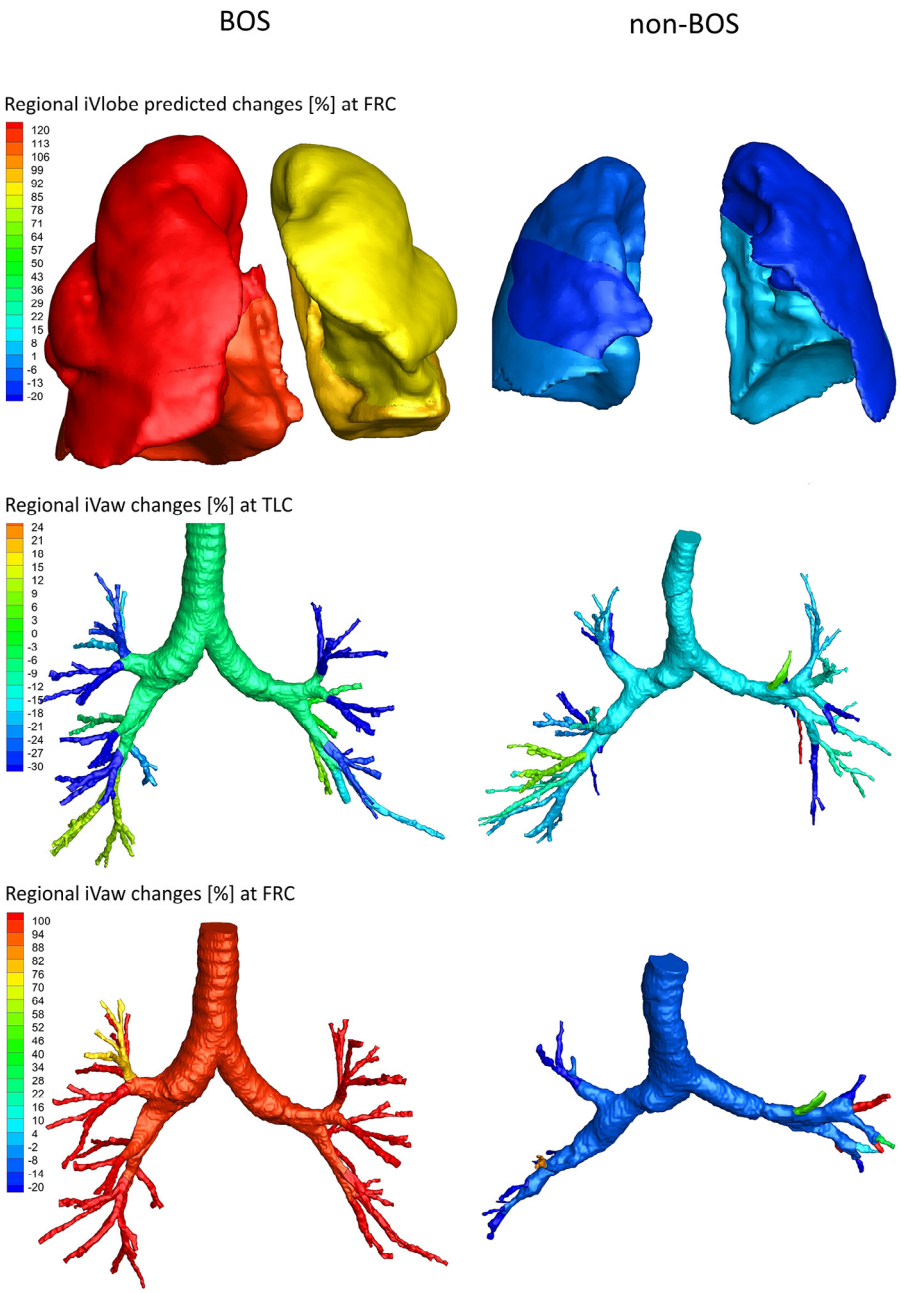

Figure 6. Functional respiratory imaging visualization of the changes in lobar volume at FRC, and airway volumes at FRC and TLC of BOS and non-BOS patients (60 years old, male, and 59 years old, female, respectively), 4 and 2 years after the initial evaluation. Both patients underwent a bilateral lung transplant. During this period, the patient with BOS had a reduction of 11.85% in FEV_1 and the non-BOS patient had a reduction of 7.36% in FEV_1. The regions experiencing a volume reduction appear in *blue tones*, whereas the regions in *yellow* and *red tones* represent an increased volume in comparison with the baseline scan. Regions in *green* represent almost no change. Lobes are shown on their anatomically correct position relative to each other; thin lines represent fissures between adjacent lobes. BOS, bronchiolitis obliterans syndrome; FRC, functional residual capacity; iVaw, imaging airway volume; iVlobe, imaging lobar volume; TLC, total lung capacity. (Color version of figure is available online.)

FRI features such as right middle lobe volume at TLC and right upper lobe volume at FRC. Eventual BOS developers tend to present at baseline with smaller right upper lobe volume at FRC and smaller right middle lobe volume at TLC. Accuracies in classification based on three features (3D classification) range from 51% to 85%. The maximal accuracy of 85% is obtained by combining baseline FRI features such as right middle lobe volume at TLC, right upper lobe airway resistance at FRC, and central airway surface at FRC. For this model, a sensitivity of 73.3% and a specificity of 92.3% were obtained. Positives were assigned to BOS developers and negatives were assigned to non-BOS developers. Eventual BOS developers tend to present at baseline with higher right upper lobe airway resistance at FRC, smaller right middle lobe volume at TLC, and lower central airway surface at FRC.

DISCUSSION

The current definition of BOS is based on a sustained and otherwise unexplained decline in FEV_1. However, pulmonary function tests have limited ability to detect its onset before the development of irreversible decline in lung function, are insensitive to early disease, and can be confounded by mixed changes (eg, combination of restrictive and obstructive pathophysiology). FRI is a validated quantitative imaging technique that has been shown to be more sensitive than pulmonary

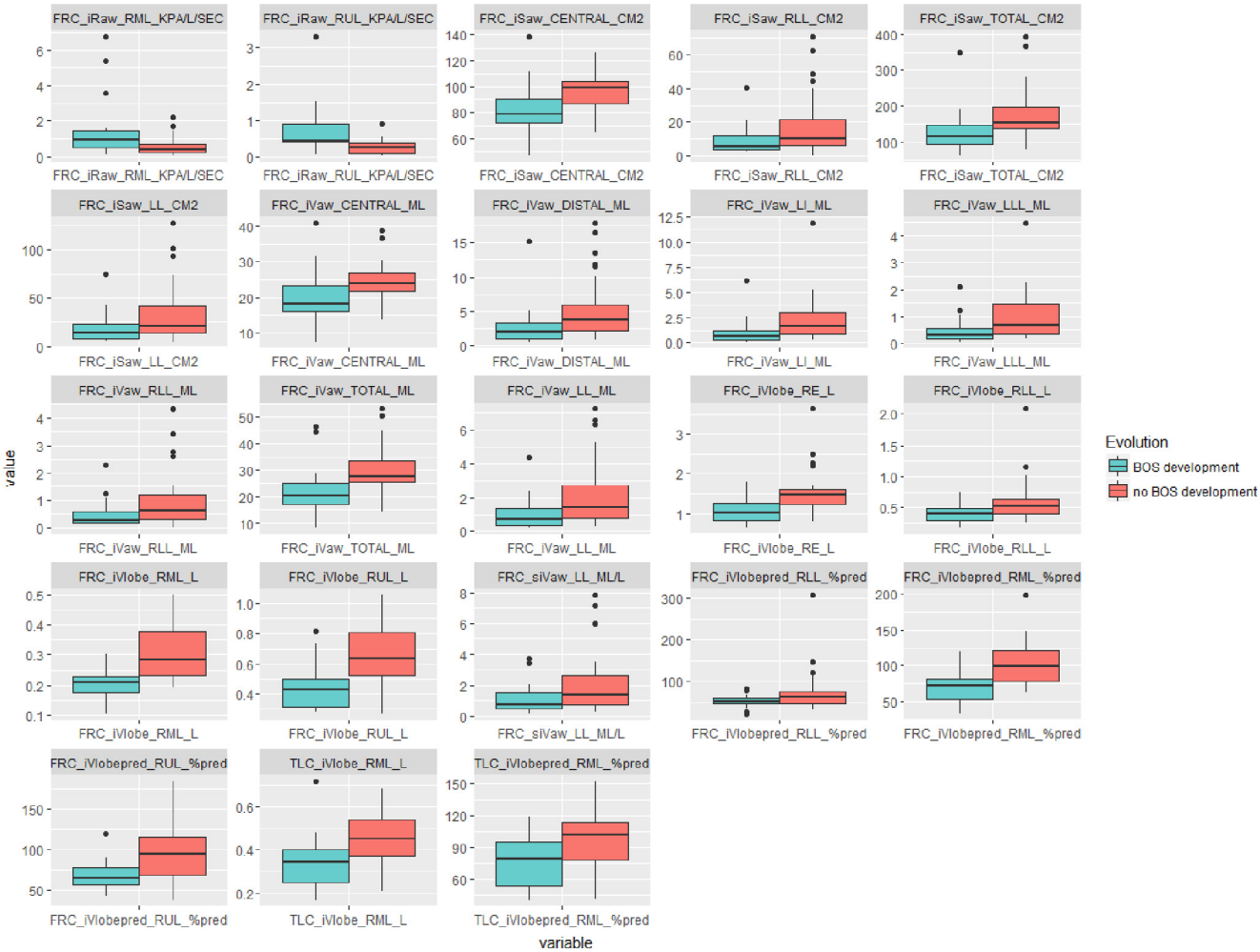

Figure 7. Significant baseline qCT predictors for BOS development (Student *t* test). Please see Supplementary Figure S1 for individual detailed box plots. CM2, square centimeter; FRC, functional residual capacity; iRaw, imaging airway resistance; iSaw, imaging airway surface; iVaw, imaging airway volume; iVlobe, imaging lobar volume; iVlobepred, image-based lobar volume [percent predicted]; LL, lower lobes (left lower lobe + right lower lobe); LLL, left lower lobe; ML, milliliter; RE, right lung; RLL, right lower lobe; RML, right middle lobe; RUL, right upper lobe; siVaw, specific image-based airway volume; TLC, total lung capacity.

TABLE 5. Accuracies for One-, Two-, and Three-dimensional Machine Learning Classification Based on Best Combinations of Baseline Predictors

Dimension (Number of Features)	Accuracy (%)	Baseline Features
1	76	Central airway volume (iVaw) at FRC
1	76	Total airway volume (iVaw) at FRC
2	83	Lobe volume (iVlobe) of RML at TLC
		Lobe volume (iVlobe) of RUL at FRC
3	85	Lobe volume (iVlobe) of RML at TLC
		Airway resistance (iRaw) of RUL at FRC
		Central airway surface (iSaw) at FRC

FRC, functional residual capacity; iRaw, imaging airway resistance; iSaw, imaging airway surface; iVaw, imaging airway volume; iVlobe, imaging lobar volume; RML, right middle lobe; RUL, right upper lobe.

function tests primarily because of its capacity to obtain regional information and to characterize early structural and functional changes, potentially enabling detection of disease at an earlier stage (15).

Multiple studies have suggested that HRCT could be useful in the diagnosis of BOS after LTx; however, its clinical value has not yet been proven because of inconsistent findings (7,16,17). Nonetheless, two more recent publications demonstrate promising results in using advanced quantitative analysis of HRCT in LTx patients to improve the accuracy of diagnosis of BOS (18) and in predicting functional parameters such as FEV_1 from qCT metrics specifically obtained from the transplanted lung in unilateral LTx (19). In our study, CT scans obtained after LTx were quantitatively analyzed using FRI to investigate how multiple quantitative imaging parameters correlate with the onset of BOS and to differentiate the mechanism accounting for FEV_1 decline, whether related to bronchiolitis obliterans or a reversible cause, such as a pulmonary infection or pulmonary edema.

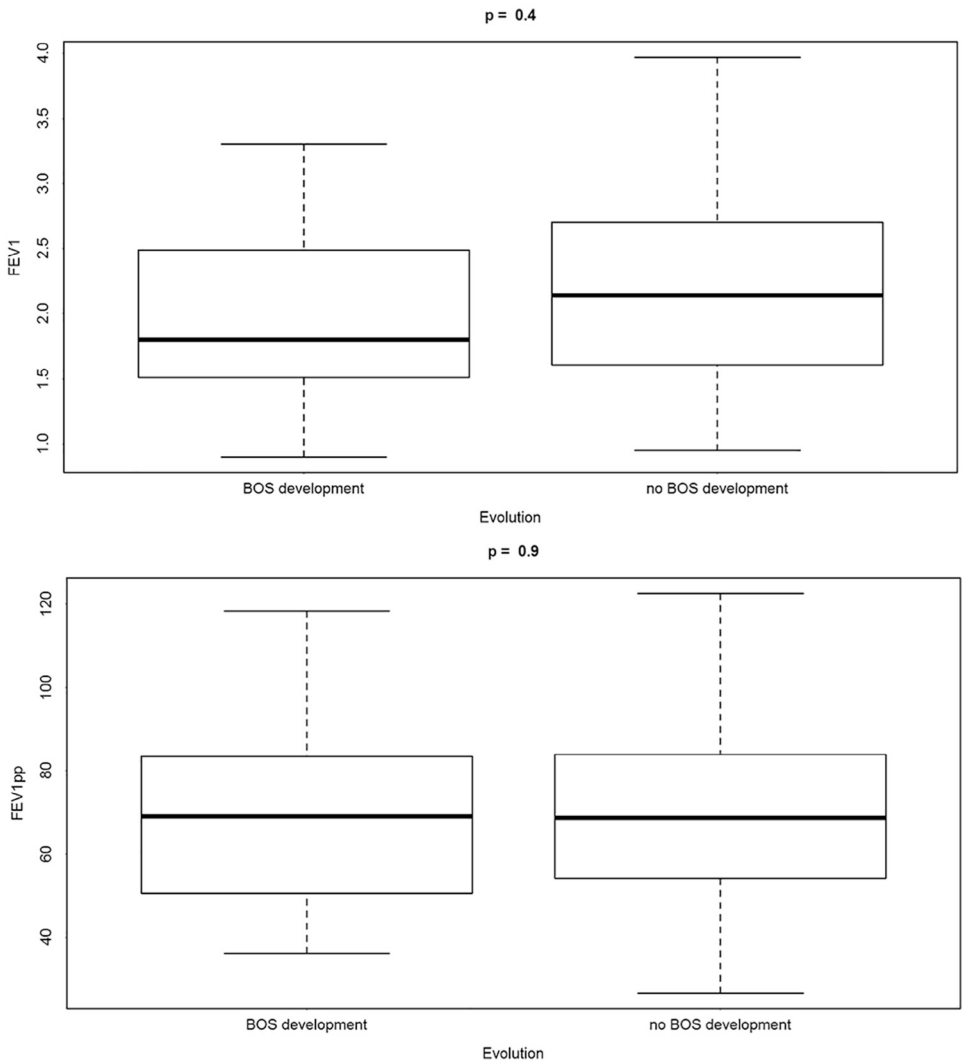

Figure 8. Baseline FEV_1 and FEV_1 (% predicted) are not significant predictors of eventual BOS development. BOS, bronchiolitis obliterans syndrome; FEV_1, forced expiratory volume in the first second.

FRI could distinguish the onset of BOS from other reversible causes in patients that underwent LTx and presented with FEV_1 decline. The decrease in FEV_1 in non-BOS patients was correlated with a decrease in the central airway volume at TLC. On the other hand, BOS patients experienced an increase in lung volume and central airway volume at FRC with decreasing FEV_1.

We hypothesize that these findings reflect an increase in the extent of air trapping and peribronchiolar fibrosis related to the progressive airflow obstruction, which characterizes the BOS phenotype of CLAD after LTx. Previous studies have also shown evidence of air trapping on expiratory CT scans and have pointed this as an indicator of the small airway disease that underlies BOS (1,16,20). On the other hand, changes in lung structure and airways for the non-BOS cohort were more evident at TLC and in an opposite direction (decrease in central airway volume), illustrating that for these patients, the nonsustained decline in FEV_1 is not associated with obliterative bronchiolitis (as would be expected with BOS), but rather with large airway bronchial wall thickening (resulting in decreases in central airways luminal volume), reflecting bronchitis or interstitial edema, as these changes were by definition reversible (eg, these patients recovered their FEV_1 and did not develop BOS).

From a pathophysiological point of view, our results seem to be concordant with these hypotheses. Bronchiolitis obliterans is a small airway disease, which in CT images is often reflected by hyperinflation and bronchodilation at the expiratory (FRC) scan. Respiratory infections (especially acute bronchitis and bronchopneumonia), on the other hand, predominantly affect the central airways leading to less prominent changes at expiration than at inspiration, where bronchial wall thickening with decreased large airway luminal volume may be the predominant effect. These different pathophysiological expressions likely support the differences in behavior of the qCT metrics that we have observed between FRC and TLC scans in LTx patients with a decline in FEV_1.

Furthermore, it should be noted that in most bilateral transplantation patients who developed BOS, a general trend of differences in hyperinflation for the left and right lungs could be seen. The representative BOS patient in Figure 6 is a perfect example of this phenomenon. We believe, and this is merely a hypothesis, that internal airflow redistribution due to mechanical properties specific for each lung (compliances) may be correlated with this occurrence. These trends will be subject to further research.

For each of the multidimensional classification tasks, ML with local and global FRI features determined the set of features that are most predictive of BOS outcome. All significant biomarkers at baseline may play a role in eventual outcome. However, ML, as it is used in this study, should be considered a tool to enable the most accurate prediction in each multidimensional space by clustering the different cohorts in the most effective way possible for the given order of dimensions. Classification in higher order dimensional spaces is certainly conceivable; however, our objective was to show that, based on a relative low amount of baseline qCT FRI features (up to 3), highly accurate predictions are still feasible.

Mixed effects models suggest that evolution toward onset of BOS is characterized by increasing lobe and airway volumes at FRC, likely due to increased hyperinflation. However, the ML classification results show that at baseline, lobe and airway volumes in the developing BOS cohort are smaller than normal ($\%P << 100\%$). The onset of BOS could therefore be related to underexpansion of the transplanted lung followed by increases in lobe and airway volumes. Considering that this increase in lobe and airway volumes will bring the parameters closer to the mean of healthy individuals, although not in a sustainable manner, these increased volumes could explain the limited sensitivity of FEV_1 to detect early onset of BOS. The fact that baseline FEV_1 and FEV_1 as percent predicted are not significant in predicting eventual BOS development suggests that in early phases of BOS, the compensatory nature of healthy areas of the transplanted lungs is still able to balance the effect of diseased areas found by FRI at a regional level of analysis. Therefore, these findings support that the examination of regional structural and functional parameters is crucial in the process of early-stage BOS detection. These hypotheses will be tested in future larger scale prospective studies.

There were limitations of the present study, mostly related to its retrospective nature. The CT scans were not obtained after a consistent exam protocol with set intervals, which lead to variability in the number, interval, and frequency of available scans per patient. Scans were obtained as clinically indicated by the transplant pulmonologist. Additionally, no spirometric control was used for the paired inspiratory and expiratory CT acquisition (noting this is standard clinical practice); therefore, the precise phase of the respiratory cycle cannot be absolutely ensured for all scans (noting that poor-quality scans with inadequate respiratory maneuvers were excluded a priori by a board-certified radiologist). The identification of the BOS patients was performed based on FEV_1 (which is standard clinical practice), and there might have been variations in PFT technique, given the long span of time pertaining to our data, which could have impacted the sensitivity to detect BOS (17). Finally, the number of patients in our sample was relatively small. It is important to note that, although most of our patients did not have pathologic confirmation of the diagnosis of bronchiolitis obliterans, this is not necessary and is rarely performed in clinical settings. The clinical diagnosis of BOS does not require pathologic confirmation.

Nevertheless, the results illustrate the potential of FRI-derived qCT imaging biomarkers to assist in the early diagnosis of BOS and in the elucidation of the etiologic mechanism accounting for FEV_1 decline, whether due to true onset of BOS or from a reversible cause such as a pulmonary infection or edema. The distinct behavior of CT metrics between BOS and non-BOS patients after LTx experiencing FEV_1 decline is potentially important for prognostication and may be helpful to guide management and therapy development for the LTx patient population.

As future directions of this research, we intend to explore whether FRI-derived qCT metrics can capture differences in behavior between the native and the transplanted lungs in unilateral LTx, and between unilateral and bilateral LTx. The latter is of interest because the type of transplant operation has an impact on survival, with bilateral transplantation being associated with higher overall survival rate in certain clinical situations (21,22), however, constrained by the limited supply of donor organs relative to the demand for LTx. If quantitative regional information can be extracted from CT images and linked to the transplanted lung in unilateral LTx, this may provide a more accurate way to diagnose early-stage BOS and could possibly serve as a predictor of future disease. By definition, PFT can only capture global information (the combined pulmonary function of the allograft and native lung in a single LTx situation) and therefore may be particularly insensitive to early functional and structural changes in the unilateral LTx population. By using qCT methods such as FRI, changes in the transplanted and nontransplanted lung can be assessed separately to improve prediction of early BOS onset.

REFERENCES

1. Hayes D. A review of bronchiolitis obliterans syndrome and therapeutic strategies. J Cardiothorac Surg 2011; 6:92.
2. Verleden GM, Raghu G, Meyer KC, et al. A new classification system for chronic lung allograft dysfunction. J Heart Lung Transplant 2014; 33:127–133.
3. Hachem RR, Trulock EP. Bronchiolitis obliterans syndrome: pathogenesis and management. Semin Thorac Cardiovasc Surg 2004; 16:350–355.
4. Estenne M, Maurer JR, Boehler A, et al. Bronchiolitis obliterans syndrome 2001: an update of the diagnostic criteria. J Heart Lung Transplant 2002; 21:297–310.
5. Todd JL, Palmer SM. Bronchiolitis obliterans syndrome: the final frontier for lung transplantation. Chest 2011; 140:502–508.
6. Brugière O, Pessione F, Thabut G, et al. Bronchiolitis obliterans syndrome after single-lung transplantation*: impact of time to onset on functional pattern and survival. Chest 2002; 121:1883–1889.
7. Miller WT, Jr, Kotloff RM, Blumenthal NP, et al. Utility of high resolution computed tomography in predicting bronchiolitis obliterans syndrome following lung transplantation: preliminary findings. J Thorac Imaging 2001; 16:76–80.

8. Meyer KC, Raghu G, Verleden GM, et al. An international ISHLT/ATS/ERS clinical practice guideline: diagnosis and management of bronchiolitis obliterans syndrome. Eur Respir J 2014; 44:1479–1503.
9. Thompson BR, Ellis MJ, Stuart-Andrews C, et al. Early bronchiolitis obliterans syndrome shows an abnormality of perfusion not ventilation in lung transplant recipients. Respir Physiol Neurobiol 2015; 216:28–34.
10. De Backer J. *Method for determining treatments using patient-specific lung models and computer methods*. Google Patents; 2014.
11. De Backer JW, Vos WG, Vinchurkar SC, et al. Validation of computational fluid dynamics in CT-based airway models with SPECT/CT. Radiology 2010; 257:854–862.
12. Vinchurkar S, De Backer L, Vos W, et al. A case series on lung deposition analysis of inhaled medication using functional imaging based computational fluid dynamics in asthmatic patients: effect of upper airway morphology and comparison with in vivo data. Inhal Toxicol 2012; 24:81–88.
13. De Backer JW, Vos WG, Devolder A, et al. Computational fluid dynamics can detect changes in airway resistance in asthmatics after acute bronchodilation. J Biomech 2008; 41:106–113.
14. Backer LAD, Vos W, Backer JD, et al. The acute effect of budesonide/formoterol in COPD: a multi-slice computed tomography and lung function study. Eur Respir J 2012; 40:298–305.
15. De Backer L, Vos WG, Salgado R, et al. Functional imaging using computer methods to compare the effect of salbutamol and ipratropium bromide in patient-specific airway models of COPD. Int J Chron Obstruct Pulmon Dis 2011; 6:637–646.
16. Bankier AA, Van Muylem A, Knoop C, et al. Bronchiolitis obliterans syndrome in heart-lung transplant recipients: diagnosis with expiratory CT. Radiology 2001; 218:533–539.
17. Choi YW, Rossi SE, Palmer SM, et al. Bronchiolitis obliterans syndrome in lung transplant recipients: correlation of computed tomography findings with bronchiolitis obliterans syndrome stage. J Thorac Imaging 2003; 18:72–79.
18. Barbosa EM, Jr, Simpson S, Lee JC, et al. Multivariate modeling using quantitative CT metrics may improve accuracy of diagnosis of bronchiolitis obliterans syndrome after lung transplantation. Comput Biol Med 2017; 89:275–281.
19. Mortani Barbosa EJ, Jr, Shou H, Simpsom S, et al. Quantitative computed tomography metrics from the transplanted lung can predict forced expiratory volume in the first second after lung transplantation. J Thorac Imaging 2017; doi:10.1097/RTI.0000000000000307; Epub ahead of print.
20. Berstad AE, Aaløkken TM, Kolbenstvedt A, et al. Performance of long-term CT monitoring in diagnosing bronchiolitis obliterans after lung transplantation. Eur J Radiol 2006; 58:124–131.
21. Finlen Copeland CA, Snyder LD, Zaas DW, et al. Survival after bronchiolitis obliterans syndrome among bilateral lung transplant recipients. Am J Respir Crit Care Med 2010; 182:784–789.
22. Ng LY, Paul N, Patsios D, et al. Imaging of lung transplantation: review. Am J Roentgenol 2009; 192(3_supplement):S1–S13.

SUPPLEMENTARY DATA

Supplementary data related to this article can be found at https://doi.org/10.1016/j.acra.2018.01.013.